

Anatomy of the Pig

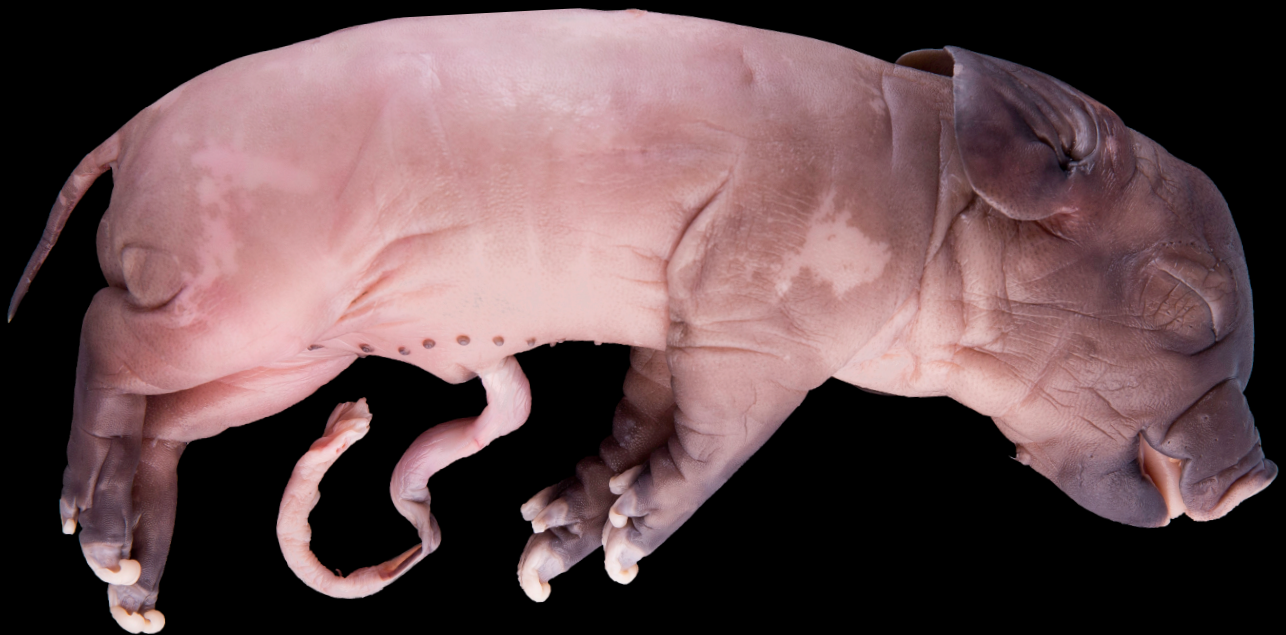By Tori Lev




Fetal Pig Dissection

Humans and fetal pigs share very similar anatomy as they are both mammals. Fetal pigs are also a popular choice for dissections as they are a bi-product of the pork industry, therefore as long as people retain their love for bacon, they will always be available in abundance. Furthermore, fetal tissue is soft and easy to cut through, making it an ideal specimen, especially for

intermediate school. Pigs are also important to study because recent research has found that they are so similar to humans that their heart tissues can be used for human transplants, after the tissue is treated to reduce potential rejection. For this article, two nine inch pigs were dissected.



Key Terms



Dorsal - the back

Ventral - the front (belly-side)

Median - the middle/central

Median plane - divides body into two similar halves

Lateral - the side

Anterior - the front (head-end)

Posterior - the back (tail-end)

Proximal - situated near the point of attachment on body

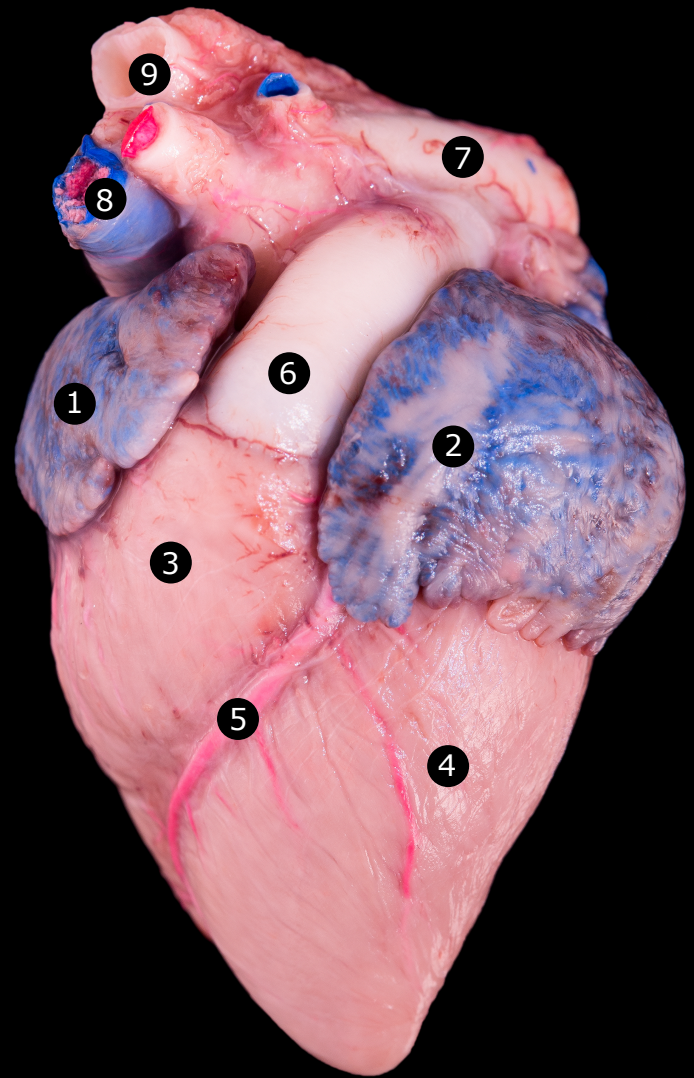
Distal - farthest away from point of attachment on body

Superficial - near the surface

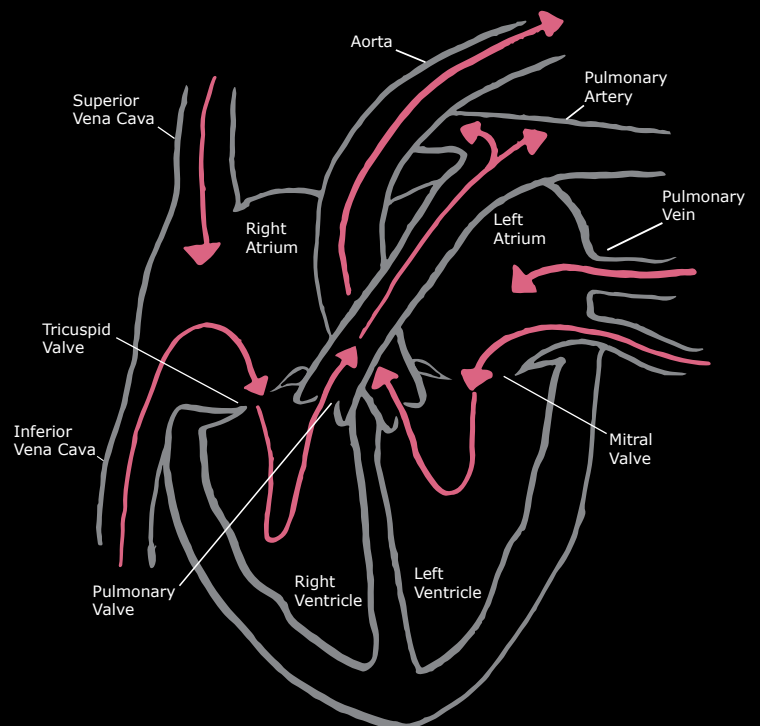
Deep - below the surface

The Heart

The heart and lungs are both located in a region of the pig known as the thoracic cavity, which is separated from the digestive system by the diaphragm, a thin, sheet-like muscle. Between the lungs we find the heart swaddled in the pericardial sac. Here we can begin to see that the heart is separated into four chambers - the right and left atrium as well as the right and left ventricle. The right atrium is the ear-shaped section of the heart labeled "1" on the figure to the right; it receives blood from the body back to the heart via the vena cava (see diagram below). Blood flows from the right atrium to the right ventricle - located just below the right atrium - through the tricuspid valve. From there, the blood flows through the pulmonary valve on to the pulmonary artery where deoxygenated blood is moved to the lungs. When the blood becomes oxygen-rich it is returned to the heart through the pulmonary vein to the left atrium. Similar to the right atrium, the left atrium contracts when filled forcing blood through the mitral valve into the left ventricle and backflow is prevented. The oxygen-rich blood is then transported to the aorta and distributed to the rest of the body.

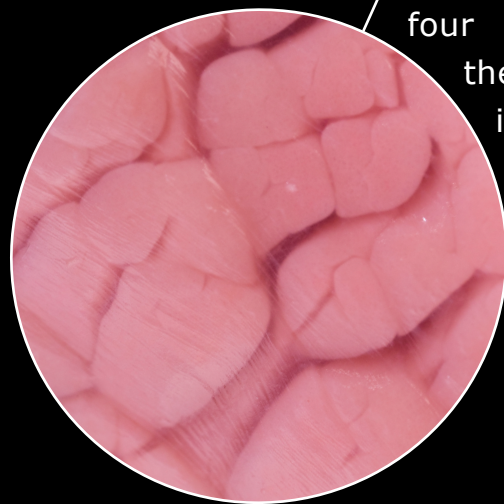


- 1 - Right atrium
- 2 - Left atrium
- 3 - Right Ventricle
- 4 - Left ventricle
- 5 - Coronary Vein
- 6 - Pulmonary trunk
- 7 - Aortic arch
- 8 - Superior vena cava
- 9 - Aorta

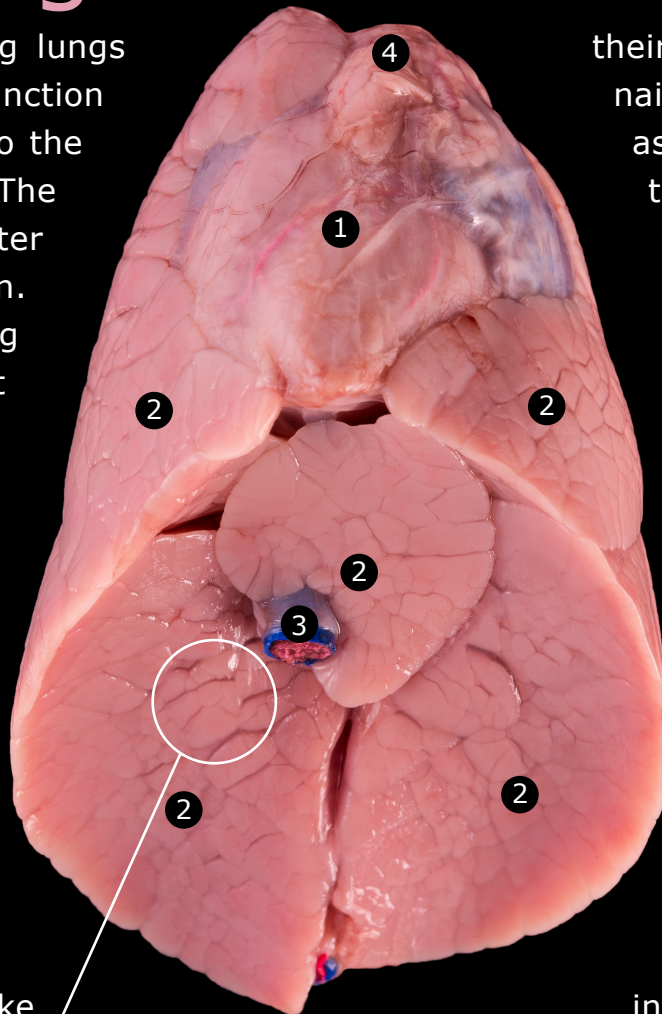


The Lungs

Both human and pig lungs have the same function of delivering oxygen to the organs of the animal. The fetal pigs lungs are flatter than those of a human. Techniques are being mastered to transplant porcine(pig) lungs into humans. The lungs have the responsibility of removing carbon dioxide and adding oxygen to blood that will then be distributed back to the body through the capillaries. Pig lungs have multiple lobes, or subdivisions, on either side. Unlike humans who have three lobes on one side and



Above: close up detail of the alveoli.



two on the other, the right lung of a pig has four lobes and the left lung is divided into three. Much like humans, pigs inhale air through

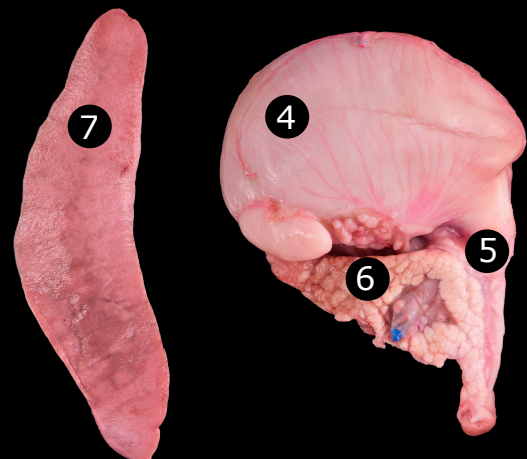
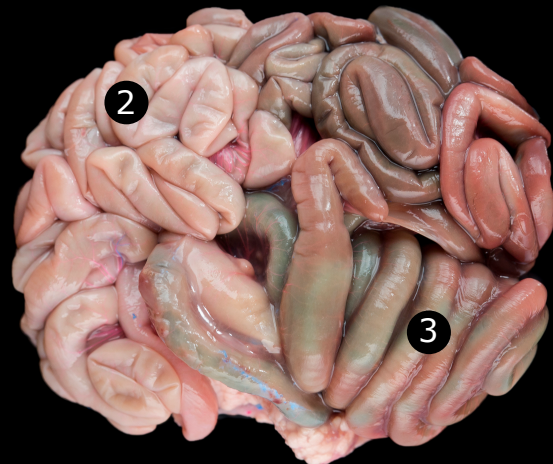
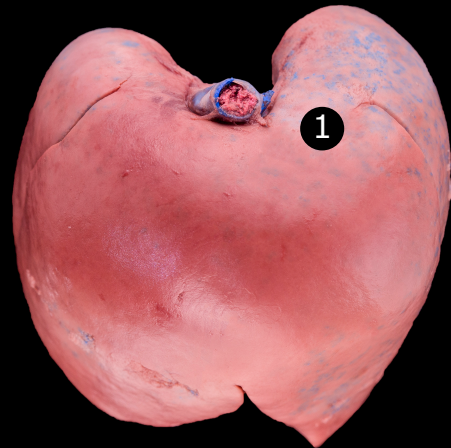
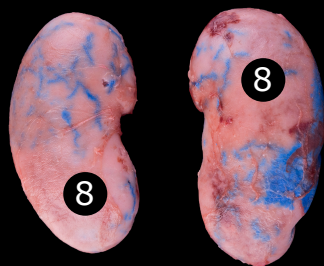
their mouth or external nares, commonly known as nostrils. From there, the air moves through the larynx to the trachea and finally on to the lungs. The lungs are spongy in texture because they are intended to have maximum surface area in order to gain the greatest possible benefit from the air taken in. The trachea that brings the air to the lungs divides into the bronchi which further divides into the bronchioles.

From here, they are sent to the alveoli, which are responsible for the spongy texture of the lungs because they are small air pockets creating a less solid structure (see figure to the left). From the alveoli comes a network of capillaries that deliver oxygen to the blood to be sent back to the heart through the pulmonary vein as discussed previously.

- 1 - Heart within the pericardial sac
- 2 - Lobes of the lungs
- 3 - Posterior vena cava
- 4 - Thymus gland

The Digestive System

This system is primarily located posterior to the diaphragm, the thin, sheet-like muscle dividing the abdominal cavity of the pig into two sections. The food to be digested enters the system through the mouth where it undergoes its initial process of digestion through chewing and mixing with saliva to begin the chemical breakdown. It then moves to the pharynx, then the esophagus to the stomach where the food is further broken down with acidic gastric juices. From there the food moves through the small intestine, where the majority of nutrient absorption occurs. It then passes through the large intestine for absorption of water and is finally excreted through the anus. Both the liver and pancreas assist in the digestive process with the secretion of digestive enzymes and insulin. These enzymes help breakdown the fats, carbohydrates, and proteins as the food passes through the small intestine. Whereas in humans the intestines are coiled flat in one layer, the pig's intestines are coiled, specifically the colon.



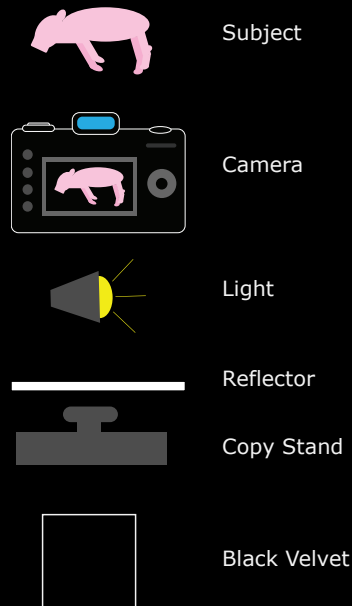

- 1 - Liver
- 2 - Small intestine
- 3 - Large intestine
- 4 - Stomach
- 5 - Duodenum
- 6 - Pancreas
- 7 - Spleen
- 8 - Kidneys

Photographic Technique

When photographing the fetal pig in its entirety as well as its various internal anatomy, I set up white reflectors surrounding the subject, shining light on two sides parallel each other to reflect back onto the subject. The camera was set up on a copy stand, so rather than a typical horizontal path it was vertical. To achieve a black background I placed the subject onto a clean sheet of glass that was held over a sheet of black velvet with wood blocks.

All images were made using the Canon 6D, either a 100mm macro or 65mm macro lens.

Top-down view



Subject

Camera

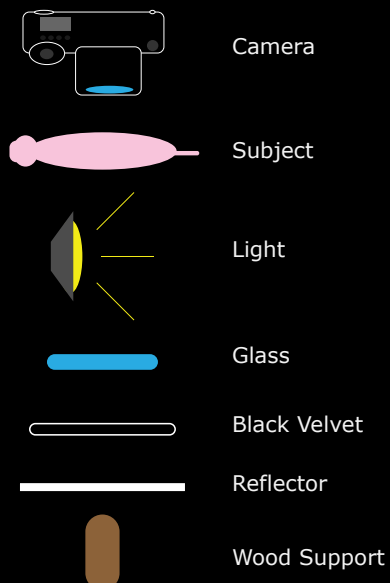
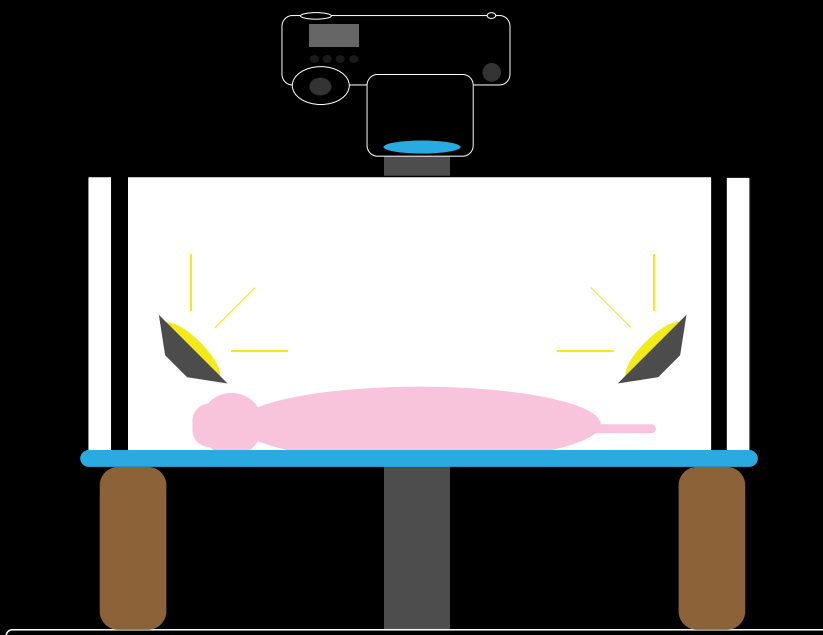
Light

Reflector

Copy Stand

Black Velvet

Side view



Camera

Subject

Light

Glass

Black Velvet

Reflector

Wood Support

About the Author

Tori is a third year in the Biomedical Photographic Communications program at the Rochester Institute of Technology; she is graduating this year. Her biggest passions in life are education and research, which drive her to pursue a career in clinical photography. During this past summer she took an internship at the University Hospital of Wales where she shadowed the clinical photography staff and worked on an



independent project photographing anesthetic equipment. When not spending time at the hospital, she was seeking out new adventures by traveling around the United Kingdom. Tori enjoys finding new places and exploring the natural world around her. When she is not going on one of these adventures, she is spending her time volunteering with Habitat for Humanity or participating in one of the clubs she is a part of.

To contact the author, please email tlev@live.com

Acknowledgments



Nebraska Scientific

Thank you to Nebraska Scientific for the fetal pig specimens. The two fetal pigs were sent in a very timely fashion and in pristine condition.



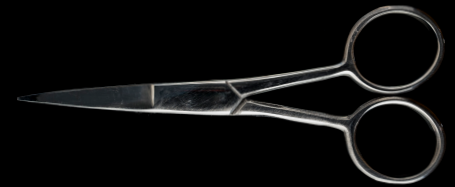Finger Lakes Mini Pigs

Thank you to Johanna at Finger Lakes Mini Pigs for being flexible and allowing me to photograph their nine-day-old teacup piglets for the cover image.



RIT Photo Equipment Cage


Thank you to the equipment cage for allowing me the opportunity to use photographic equipment that I would typically not have access to.



Pork is the name for the meat derived from pigs; it is the most consumed meat worldwide.

Did you know...

Resources



- "Anatomy of the Heart." Biological Sciences. Santa Barbara City College, 2003. Web. 2015. <<http://www.biosbcc.net/b100cardio/htm/heartant.htm>>.
- Carter, Morgan Brown. "Virtual Fetal Pig Dissection." Whitman College. Ed. Thomas Knight. Whitman College, 10 May 2011. Web. 2015. <<https://www.whitman.edu/academics/departments-and-programs/biology/virtual-pig>>.
- "Digestive System of the Pig: Anatomy and Function." The Pig Site. The Pig Site, 10 June 2009. Web. 2015. <<http://www.thepigsite.com/articles/2749/digestive-system-of-the-pig-anatomy-and-function/>>.
- "Dissecting a Porcine (Pig) Heart." What Does a Real Heart Look Like? (1997): n. pag. 25 July 1997. Web. <<http://www.sci.utah.edu/~macleod/bioen/be6000/labnotes/l1-dissect/heartdissection-page1.pdf>>.
- "Fetal Pig Anatomy." Fetal Pig Anatomy. N.p., n.d. Web. 2015. <http://bioserv.fiu.edu/~walterm/human_online/labs/fetal_pig/fetal_pig_anatomy.htm>.
- "Fetal Pig Dissection Guide." Fetal Pigs Are Good Dissection Specimens. Biology Department of Goshen College, Jan. 1998. Web. <<https://www.goshen.edu/bio/pigbook/dissectionadvantages.html>>.
- "Fetal Pig Dissection Pictures." Fetal Pig Dissection Pictures. N.p., n.d. Web. <<http://home.apu.edu/~jsimons/Bio101/PigDissectionGuide.htm>>.
- "Fetal Pig Dissection." Pig Dissection. BiologyCorner.com, n.d. Web. 2015. <http://www.biologycorner.com/worksheets/fetal_pig_dissection.html>.
- Holstad, Grace E. An Introduction to the Anatomy of the Fetal Pig. Northfield: Department of Biology St. Olaf College, 1950. Pig Dissection. Web. 2015. <<http://hdl.handle.net/2027/coo.31924002901944>>.
- "Human/Pig Comparisons." Fetal Pig Dissection Guide. N.p., Jan. 1998. Web. 2015. <<https://www.goshen.edu/bio/pigbook/humanpigcomparison.html>>.
- "The Intermediate Guide on the Fetal Pig." (n.d.): n. pag. Pig Dissection Lab. Web. 2015. <http://www.epcc.edu/Biology/Documents/Pig%20Lab%202015/Pig_Dissection_Lab.pdf>.
- "Pig Facts and Trivia." New Zealand Pork. N.p., n.d. Web. 2015. <<http://www.nzpork.co.nz/media-and-schools/pig-facts>>.
- Schneider, Jeff. "Fetal Pig Glossary." Science by Slim. N.p., 21 May 2007. Web. <https://js082.k12.sd.us/my_classes/advanced_biology/pig_dissection/fetal_pig_glossary.htm>.
- Seowon, and Kei. "Lungs, Bronchi, Bronchioles, Pleura." How to Dissect a Fetal Pig. N.p., n.d. Web. <<http://fetal-pig-dissection.weebly.com/lungs-bronchi-bronchioles-pleura.html>>.
- "Tell Me About Fetal Pigs." Nebraska Scientific. Nebraska Scientific, 2015. Web. <http://www.nebraskascientific.com/Science_Tips/Tell_me_about_Fetal_Pigs/>.
- Uzwiak, Dana, and Aspen Reese. "Lab 10: Cardiovascular and Respiratory Systems." Rutgers, n.d. Web. <http://bio.rutgers.edu/~gb102/lab_10/>.
- Westling, Bruce. "The Human Heart." The Human Heart. N.p., 2001. Web. 2015. <<http://science.jburroughs.org/resources/heart/hearttitle.html>>.

